

The Evidence Basis of Extra-osseous Talotarsal Stabilization (EOTTS)

When compared to other surgical treatment options, the benefits far outweigh any potential risks.

BY MICHAEL E. GRAHAM, DPM

There has been a struggle over the past few decades to gain acceptance by the insurance industry to reimburse surgeons and facilities for internally re-aligning and stabilizing one of the most important weight-bearing joints, the talotarsal joint (TTJ). Their primary excuse for not paying, “covering” this life-changing solution, is the lack of scientific evidence. They label extra-osseous talotarsal stabilization (EOTTS) as “experimental or investigational.” How long they can continue to call it that remains a mystery. This extremely crucial treatment option, EOTTS, serves as an important piece of the puzzle to maintain balance, stability, and alignment within the foot and proximal musculoskeletal structures.

The Importance of an Aligned and Stable TTJ

The TTJ, acetabulum pedis, is the foundation joint of the body. It is responsible for handling the vertical forces

from above, and the weight-bearing surface from below. Approximately, half of those forces should act on the posterior talocalcaneal facet and the remaining forces act on the facets anterior to the sinus tarsi.

When standing, the talus should be neutral to slightly pronated on the calcaneus and navicular.^{2,4} TTJ range of motion, during ambulation, consists of approximately two thirds supination and only a slight amount of pronation at the beginning of the mid-stance phase. It is more important that the TTJ is in a supinated position throughout the majority of the contact phase of the gait cycle. This position strengthens the joints within the foot structure to increase the efficiency of the complex foot mechanism.

Walking is the most common form of human locomotion. The average person takes approximately 6,000-10,000 steps a day. This adds up to 72 million steps by the age of 40, and over 100 million steps by the age of 60. A stable and aligned TTJ creates an efficient transfer of weight-bearing forces and minimal amount of muscle activity.

Recurrent Talotarsal Joint Dislocation (RTTJD)

A pathologic condition exists where the weight-bearing alignment and stability of the TTJ is lost. TTJ instability leads to mis-alignment within the TTJ, resulting in an excessive medial, anterior, and/or plantarflexion of the talus with the calcaneus and navicular. The articular facets of the talus on the calcaneus and navicular are no longer in constant congruent contact. This orthopedic abnormality is referred to as a dislocation.

To be clear, a dislocation is defined as the incongruity of articular facet alignment/contact. There are many varieties of dislocation, just like there are many types of fractures. A stress fracture is still a fracture. A mild ingrown toenail is still an ingrown toenail. Dislocations are further classified

as acute, non-acute, partial, and total.

RTTJD is a dynamic pathology where the articular facets of the TTJ continuously transition from

normal to abnormal contact during the weight-bearing positions. The TTJ facets are in normal alignment during non-weight-bearing and transition to incongruity while weight-bearing. This deformity can be documented by simply taking a non-weight-bearing lateral radiograph of the rearfoot compared to a weight-bearing radiograph.

The destructive nature of this deformity is due to imbalance of weight-bearing forces that should be passing posteriorly but are now acting anteriorly on the medial column of foot bones. Even worse is the prolonged unlocking of the foot structure when it should be locked and supinated, to propel the foot forward. The combination of an unlocked, loose-joint foot structure, combined with excessive forces acting on it, creates a loss of homeostasis.

Ligaments contain neurosensors, Golgi bodies that detect excessive joint motion.⁵ They trigger a reflex mechanism to the muscle-tendon complex to contract. This is an attempted form of compensation for the unnatural

Continued on page 114

The TTJ, acetabulum pedis, is the foundation joint of the body.

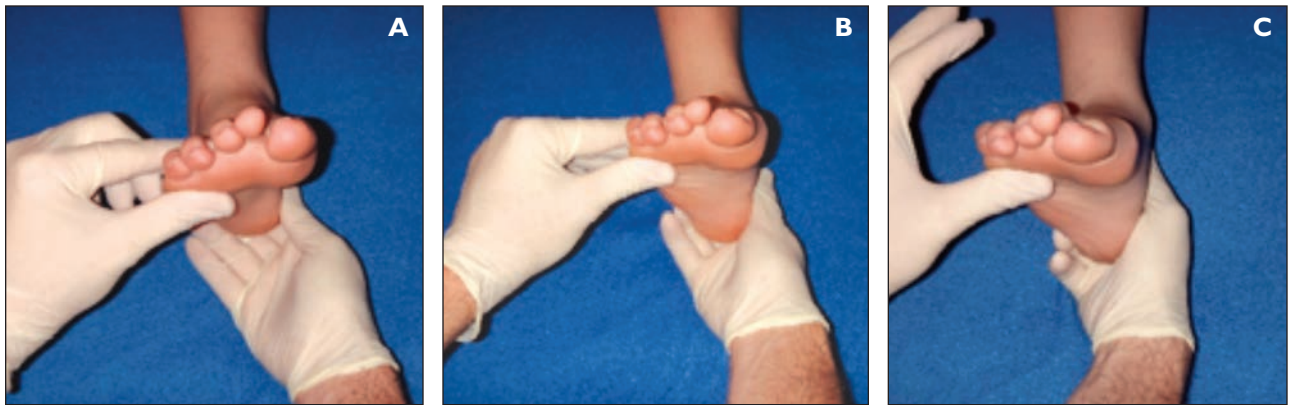

Figure 1: Clinical talotarsal joint range of motion evaluation. A. Neutral position. B. Normal pronation, <6 degrees. C. Excessive pronation >6 degrees.

joint instability. Soft tissues can compensate for these excessive forces for only a specific, limited time period. Eventually, a critical threshold is reached where the soft tissues are no longer able to handle the force. This is when soft tissue pathology/symptomatology begins. The soft tissue pathology will be nearly impossible to repair until the realignment and stability of the TTJ is achieved. The associated joints will also become diseased due to the chronic disease process.

There is no evidence that RTTJD will auto-repair. It will not get better. It is a progressive orthopedic deformity. Soft and osseous tissue adaptations will occur according to Wolff and Davis' laws. This is one of the reasons why RTTJD leads to tissue and joint destruction within the foot and to the proximal musculoskeletal structures. This is also why there is a strong medical necessity to maintain the alignment and stability of the TTJ.

A diagnosis of RTTJD can be observed clinically and confirmed with specific radiographic findings (Figures 1 & 2).

Clinical Exam

- Non-weight-bearing—TTJ range of motion >6 degrees of pronation (note: this is not calcaneal inversion/eversion of the posterior subtalar joint, rather talotarsal range of motion)
 - Weight-bearing observations can include:
 - Bulging of the head of the talus on the inner ankle, giving the appearance of two inner ankle bones.
 - “Too-many-toes” sign—the ability to see more than just the fifth toe when examining at the foot posteriorly.
 - A lowering/flattening of the arch (arch height is not consistent, and therefore, not a reliable finding).
 - Calcaneal valgus (not always present).

Weight-bearing Radiographic Exam

- Lateral view
- Obliteration of the sinus tarsi, partial to full
- Talar declination angle > 21 degrees

- Plantarflexed navicular, compared to the cuboid (observation)
- Anteriorly deviated cyma/distal slide of the talus on the calcaneus (observation)
- Deviated talar first metatarsal angle
- Dorsoplantar view
- Talar 2nd metatarsal angle > 16 degrees
- Talocalcaneal angle > 40 degrees
- Talonavicular coverage > 7 degrees

Treatment of RTTJD

The primary goal of treatment is to maintain the stability and alignment of the articular facets of the TTJ. Accomplishing this goal while continuing to maintain a normal range of TTJ motion has been the preferred method over the complete elimination of TTJ range of motion. It is for that reason specifically that orthopedic innovators have tirelessly

dedicated their efforts to achieve this result. External modalities may be able to provide short-term relief to secondary symptoms attributed to RTTJD. However, the reality is that there is no evidence that external treatments can succeed at re-aligning and maintaining the articular facets of the TTJ. Evidence has proven this fact.⁶ The use of devices such as arch supports—plantar foot orthotics—provides a sub-therapeutic, short-term option in the treatment of RTTJD.

EOTTS is a time-tested, evidenced-based, soft tissue procedure where an orthopedic stent is inserted into the sinus tarsi.^{6,72} There are more than a dozen FDA-cleared devices being routinely used within the United States. In fact, these sinus tarsi stents are regularly recommended to patients by both orthopedic and podiatric surgeons globally. Their use is advocated at orthopedic and podiatric medical conferences world-wide. The use of sinus tarsi implants has been positively documented within chapters of many well-known orthopedic and podiatric textbooks. The advocacy for the EOTTS procedure has

Continued on page 115

continued to increase since its first introduction decades ago. The types of peer-review articles are summarized in Table 1 on the next page.

What is the minimum level of evidence required to consider EOTTS effective?

There seems to be a double standard for the requirements from the insurance industry to consider an evidence-based treatment. Let's approach this with the following questions in mind: What does the EOTTS procedure "fix"? Is there evidence, clinical and radiographic, that it achieves that goal? Has this procedure been shown to be safe for its intended use? Is there evidence that EOTTS provides positive patient reported outcomes? Are

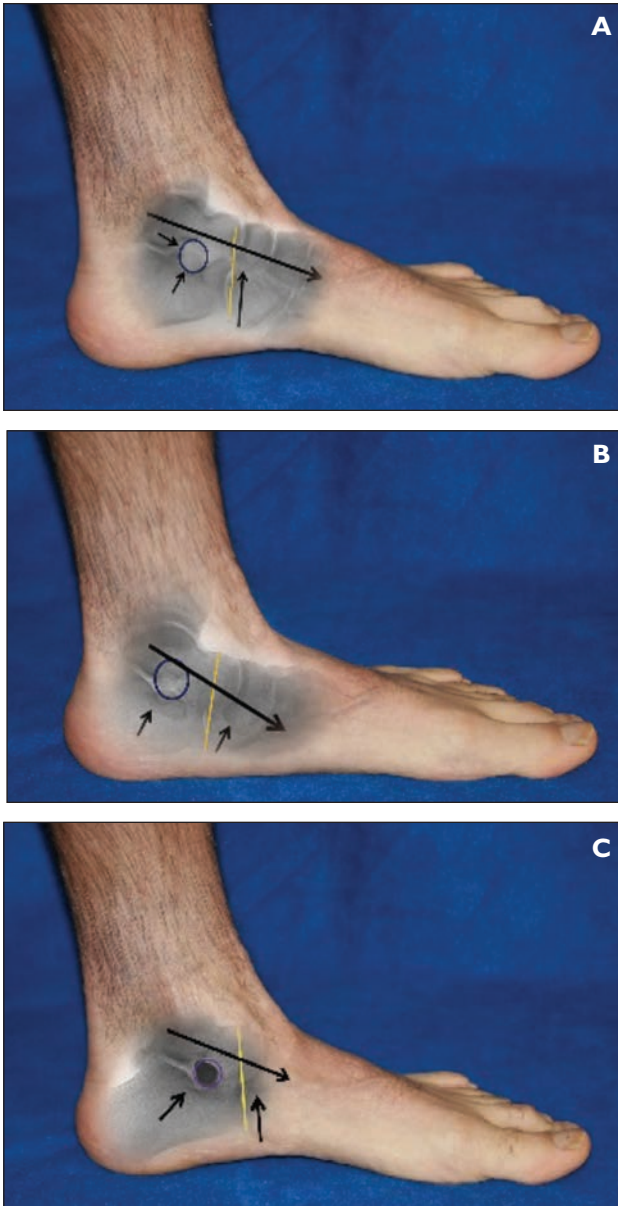


Figure 2: Combination of clinical and radiographic images showing: (A) Aligned talotarsal joint, (B) Partial talotarsal joint dislocation, (C) Post-extraosseous talotarsal stabilization.

there proven advantages of EOTTS? Do other "similar" methods realign and stabilize the TTJ? Are there any associated complications commonly reported when compared to other accepted forms of treatment?

1) Is there evidence that the EOTTS procedure maintains the stability and alignment of the TTJ clinically and radiographically?

Yes! There have been multiple published studies showing reduction/normalization of pre-EOTTS pathologic findings.

Clinical findings:^{8,11,17,19,24,50} Non-weight-bearing: TTJ range of pronatory range of motion < 6 degrees.

Weight-bearing (static/dynamic):

- Reduction of valgus alignment of the foot to lower leg
- Reduction of medial talar head bulging
- Normalization of arch height, if previously lower than normal
- Normalization of calcaneus valgus
- Reduction of "too many toes" sign
- Reduction of abductory twist
- Normalization of pronation during the gait cycle

Continued on page 116

Gait Analysis:²²

- Normalization of center of force pressures acting on the plantar surface of the foot.

Radiographic evidence:^{6,11,16,19,26,30,37,41,50,53,54,65,66}

Lateral (sagittal plane):

- Talar declination angle
- Calcaneal inclination angle
- Talar-first metatarsal angle
- Normalization of navicular position

Dorsoplantar (transverse plane):

- Talar 2nd metatarsal angle
- Talar 1st metatarsal angle
- Talocalcaneal angle
- Talonavicular coverage

2) Is there evidence that the EOTTS procedure normalizes the range of motion of the TTJ?

Yes! Simply by realigning and stabilizing the TTJ. Clinical and radiographic evidence is all that is needed. Actually, proving TTJ range of motion should not be a consideration for the evidence basis of EOTTS. A similar accepted treatment that would be a covered benefit, without question, is a subtalar joint arthrodesis. This is a functional amputation of the TTJ. The short- and long-term complications of arthrodesis are well established.^{73,74} A key advantage of EOTTS is that unlike arthrodesis, it still allows the normal TTJ range of motion to take place. It is for this reason that EOTTS should be considered a conservative surgical option over aggressive joint destructive procedures.

3) Is there evidence that the EOTTS procedure normalizes the joint forces acting on the tarsal mechanism?

Yes! Published data shows that there is a normalization of forces acting on the TTJ. There is no data to show similar results with other “accepted” forms of treatment, i.e., lateral column lengthening, medial displacement, calcaneal osteotomy, talonavicular arthrodesis, or subtalar arthrodesis.

4) Is there evidence that a patient’s quality of life is made better after undergoing EOTTS?

Yes! Re-alignment of the TTJ decreases the tissue and osseous strain within the foot and to the proximal joint structures. Ligament strain is decreased, which stops the muscle-tendon compensations. Muscles work more efficiently, and tendon strain is

decreased. Patients are able to become more physically active and report improved functional scores following EOTTS.^{11,16,20,24,26,37,53,62,65,66} EOTTS functions better than external modalities and without the risks and complications associated with other more aggressive surgical procedures.

5) What are the reported “worst case” complications?

There will always be potential risks associated with any form of treatment, no matter how conservative that

A key advantage of EOTTS is that unlike arthrodesis, it still allows the normal TTJ range of motion to take place.

treatment. The main point to grasp in this section is: does EOTTS present similar or greater risks when compared to other recognized surgical treatment options? EOTTS has been performed for many decades and it is estimated that more than 250,000 EOTTS procedures have been performed globally. Yet, only a few “complications” have been reported.⁷⁶⁻⁷⁹

Orthopedic implants such as screws, staples, pins, and plates have a history of breakage. This complication has never been reported with any titanium sinus tarsi stent. Many surgeons will “routinely” remove non-sinus tarsi stent devices that are present in their patients’ feet. EOTTS stents have a significantly lower removal rate compared to other internal forms of TTJ stabilization devices.^{8,19,20,24,29,37,62}

There are many other complications that arise from other methods of TTJ stabilization.⁷³ Subtalar joint arthrodesis is proven to cause arthritic changes to adjacent joints within six months⁷⁴—this has not been a finding associated with EOTTS. There are mal- and non-unions rates with subtalar arthrodesis procedures.⁷⁵ These are very costly complications that will never occur with EOTTS. Cutting and removing the articular surfaces of the posterior talocalcaneal joint will be associated with a loss of calcaneal-talar height. This can lead to a leg-length discrepancy; this is not found with EOTTS.

There have been only a few single-case reports of

Continued on page 117

TABLE I: Types of EOTTS Published Studies

- Pediatric Indications
- Adult Indications
- Stand-alone procedure
- Combination of EOTTS with other forms of treatment
- Clinical Improvement showing triplane correction
- Complications have been reported
- Peer-reviewed studies in orthopedic journals
- Peer-reviewed studies in podiatric journals
- Domestic (USA) based studies
- International based studies
- Prospective studies
- Retrospective studies
- Radiographic improvement studies
- Cadaver studies
- Fine-element analysis studies
- Biomechanic studies
- Explantation rate studies

complications following the EOTTS procedure.⁷⁶⁻⁷⁹ These “worst case” situations could have been prevented if their physician had intervened earlier. Both were due to a mal-positioned stent. The sinus tarsi stent should have been re-positioned or simply removed. The surgeon observed the mal-placed stent but simply allowed the patient to continue to walk without addressing it. This would be similar to the mal-placement of a screw that extended into a joint. Eventually, that mal-positioned screw would lead to arthritic changes within the joint. It was surgeon error, not device error. There was another case where an athletic patient had the EOTTS procedure and subsequently developed a stress fracture of the talus.⁷⁹ The correlation between the talar stress fracture and the sinus tarsi stent was not “proven.” Talar stress fractures occur in highly active patients without a sinus tarsi implant in their foot.⁸⁰ If the primary cause of the stress fracture was the stent, then there should be more reported cases—not just a single case of a patient who competed in “at risk/impact” sports for many years.

The bottom line is that any less-than-favorable situations arising from the insertion of a sinus tarsi stent is significantly less frequent than complications associated with other orthopedic stabilization devices. This proves that sinus tarsi implants provide a conservative option in the treatment of RTTJD with fewer complications.

The number of physicians and the multi-millions of dollars needed for the “desired” prospective, outcome-based studies on EOTTS are just not available.

There are also many secondary supportive evidence-based publications proving the powerful role of the EOTTS procedure to other important structures such as:

- Reduction of strain on the posterior tibial tendon by 51%⁴²
- Reduction compression forces within the tarsal tunnel 34% and porta pedis 38%⁴⁴
- Reduction of elongation strain to the posterior tibial nerve by 43%⁴³
- Reduction of strain on the medial band of the plantar fascia by 33%⁴⁰

The accepted “conservative” recommendation for the treatment of these secondary tissue diseases does not provide any evidence to reduce the underlying destructive force acting on those tissues. These measures are only focused on the temporary masking of symptoms. This shows that EOTTS is an important aspect of treatment for many secondary pathologies.

Unrealistic evidenced-based expectations have been suggested and unfair comparisons have been made to the quality and number of patients included in published studies. These critics must realize that there is limited

funding for foot/ankle related studies compared to the prospective studies in the pharmaceutical arena, or even for more commonly performed orthopedic procedures.

Simply, the number of physicians and the multi-millions of dollars needed for the “desired” prospective, outcome-based studies on EOTTS are just not available. The demand for level 1 side-by-side comparison outcome-based studies does not always make sense. The use of a parachute while exiting a plane that is flying at 30,000 feet in the air is not evidence-based.⁸⁰ They could not find enough people to jump out of the plane without a parachute to show the efficacy of someone jumping out with a parachute.

Finally, many of the insurance carriers claim they won't cover EOTTS because it treats hyper-pronation or flat feet. Again, a double standard is used to shoot down EOTTS. One simple question must be asked. What is the primary reason a lateral column lengthening, medical displacement osteotomy, Kidner, spring ligament repair, subtalar arthrodesis, talonavicular and calcaneocuboid arthrodesis are performed? To fix a hyper-pronated, flat foot. Doesn't it make sense that a more conservative treatment with fewer risks and complications also should be covered?

Continued on page 118

.....

Summary

EOTTS is a minimally invasive procedure that exceeds the requirements of being evidence-based. The ability of a surgeon to internally realign and stabilize the TTJ, while still allowing a normal range of motion, is essential in the treatment of many lower extremity pathologies. EOTTS normalizes the forces acting within the foot structure, and instantly decreases forces acting on the bones, joints, tendons, ligaments, and neurovascular structures of the foot. Because the ankle joint is realigned, there are positive effects to the knees, hips, pelvis, and spine. This procedure is reversible. It can be used in conjunction with both external measures and other surgical procedures. This soft tissue procedure can and is commonly performed on both children and adults.

There are many reasons why EOTTS devices have been approved and are being performed in more than 70 countries. When compared to other surgical treatment options, the benefits far outweigh any potential risks. Patients who have had the EOTTS procedure have been able to increase their activity levels, increase their metabolism, decrease their weight, and improve their blood sugar levels and blood pressure. Simply put, they get their lives back. They don't have to think about whether an activity is worth the pain they once experienced when standing or walking. **PM**

Editor's Note: Readers should be aware that Podiatry Management does not specifically endorse any of the technologies, concepts, or products discussed in our "Clinical Innovations" series.

References

- ¹ Graham ME, Parikh R, Goel V, Mhatre D, Matyas A. Stabilization of joint forces of the subtalar complex via HyProCure sinus tarsi stent. *J Am Podiatr Med Asso.* 101(5):390-9, 2011.
- ² Kirby KA. Rotational equilibrium across the subtalar joint axis. *J Am Podiatr Med Assoc.* 79(1):1-14, 1989.
- ³ Kitaoka HB, Luo ZP, An KN. Three-dimensional analysis of normal ankle and foot mobility. *Am J Sports Med.* 25(2):238-42, 1997.
- ⁴ Sarrafian SK. Biomechanics of the subtalar joint complex. *Clin Orthop Relat Res.* 290:17-16, 1993.
- ⁵ Zimny ML. Mechanoreceptors in articular tissues. *Am J Anat.* 182(1):16-32, 1988.
- ⁶ Steber S, Kolodziej L. Analysis of Radiographic Outcomes Comparing Foot Orthosis to Extra-Osseous Talotarsal Stabilization in the Treatment of Recurrent TaloTarsal Joint Dislocation. *J Min Inv Orthop.* 1;1-11, 2015.
- ⁷ Xu Y, Li SC, Xu SY. Calcaneal Z Lengthening Osteotomy Combined with Subtalar Arthroereisis for Severe Adolescent Flexible Flatfoot Reconstruction. *Foot Ankle Int.* 37(11):1225-31, 2016.
- ⁸ Saxena A, Via AG, Maffulli N, Chiu H. Subtalar Arthroereisis Implant Removal in Adults: A Prospective Study of 100 Patients. *J Foot Ankle Surg.* 55(3):500-3, 2016.
- ⁹ Faldini C, Nanni M, traina F, Fabbri D, Borghi R, Giannini S. Surgical treatment of hallux valgus associated with flexible flatfoot during growing age. *Int Orthop.* 40(4):737-43, 2016.
- ¹⁰ Carr JB, Yang S, Lather LA. Pediatric Pes Planus: A state-of-the-Art Review. *Pediatrics.* 137(3):1-10, 2016.
- ¹¹ Ozan F, Dogar F, Gencer K, Koyuncu S, Vatansever F, Duygulu F, Altay T. Symptomatic flexible flatfoot in adults: subtalar arthroerei-

sis. *Ther Clin Risk Manag.* 11:1597-602, 2015.

¹² Chong DY, Macwilliams BA, Hennessey TA, Teske N, Stevens PM. Prospective comparison of subtalar arthroereisis with lateral column lengthening for painful flatfeet. *J Pediatr Orthop B.* 24(4):345-53, 2015.

¹³ Toullec E. Adult Flatfoot. *Orthop Traumatol Surg Res.* 101(1 suppl):S11-7, 2015.

¹⁴ Flynn J, Wade A, Bustillo J, Juliano P. Bridle procedure combined with a subtalar implant: a case series and review of the literature. *Foot Ankle Spec.* 8(1):29-35, 2015.

¹⁵ Shah NS, Needleman RL, Bokhari O, Buzas D. 2013 Subtalar Arthroereisis Survey: The Current Practice Patterns of Members of the AOFAS. *Foot Ankle Spec.* 8(3):180-5, 2015.

There are many reasons why EOTTS devices have been approved and are being performed in more than 70 countries.

¹⁶ Zhu Y, Xu XY. Treatment of Stage II Adult Acquired Flatfoot Deformity with Subtalar Arthroereisis. *Foot Ankle Spec.* 8(3):194-202, 2015.

¹⁷ Tarissi N, Valiee A, Dujardin F, Duparc F, Roussignol X. Reducible valgus flat-foot: assessment of posterior subtalar joint surface displacement by posterior arthroscopy during sinus tarsi expansion screwing. *Orthop Traumatol Surg Res.* 100(8 suppl):S395-9, 2014.

¹⁸ Kumar V, Clough TM. Talar neck fracture-a rare by important complication following subtalar arthroereisis. *Foot (Edinb).* 24(4):169-71, 2014.

¹⁹ De Pellegrin M, Moharamzadeh D, Strobl WM, Bidermann R, Tschauer C, Wirth T. Subtalar extra-articular screw arthroereisis (SESA) for the treatment of flexible flatfoot in children. *J Child Orthop.* 8(6):479-87, 2014.

²⁰ Jay RM, Din N. Correcting pediatric flatfoot with subtalar arthroereisis and gastrocnemius recession: a retrospective study. *Foot Ankle Spec.* 6(2):101-7, 2013.

²¹ Baker JR, Klein EE, Weil L JR, Weil LS Sr, Knight JM. Retrospective analysis of the survivability of absorbable versus non-absorbable subtalar joint arthroereisis implants. *Foot Ankle Spec.* 6(1):36-44, 2013.

²² Fitzgerald RH, Vedpathak A. Plantar Pressure Distribution in a Hyperpronated Foot Before and After Intervention with an Extra-Osseous Talotarsal Stabilization Device—A Retrospective Study. *J Foot Ankle Surg.* 52(4):432-43, 2013.

²³ Navi B, Theivendran K, Prem H. Computed Tomography Review of Tarsal Canal Anatomy with Reference To the Fitting of Sinus Tarsi Implants in the Tarsal Canal. *J Foot Ankle Surg.* 52(6):714-716, 2013.

²⁴ Bresnahan PJ, Chariton JT, Vedpathak A. Extra-Osseous TaloTarsal Stabilization using HyProCure®: Preliminary Clinical Outcomes of a Prospective Case Series. *J Foot Ankle Surg.* 52(2):195-202 2013.

²⁵ Graham, ME. Congenital Talotarsal Joint Displacement and Pes Planovalgus. *Clin Podiatr Med Surg.* 30:567-81, 2013. Abbara-Czardybon M, Wingenfeld C, Arbab D, Frank D. Options and limits of subtalar arthroereisis in childhood. *Orthopade.* 42(1):12-9, 2013.

²⁶ Garras DN, Hansen PL, Miller AG, Raikin SM. Outcome of modified Kidner procedure with subtalar arthroereisis for painful ac-

Continued on page 119

cessory navicular associated with planovalgus deformity. *Foot Ankle Int.* 33(11):934-9, 2012.

²⁷ Fernandez de Retana P, Alvarez F, Bacca G. Is there a role for subtalar arthroereisis in the management of adult acquired flatfoot. *Foot Ankle Clin.* 17(2):271-81, 2012.

²⁸ Yen-Douangmala D, Vartivarian M, Choung JD. Subtalar arthroereisis and its role in pediatric and adult population. *Clin Podiatr Med Surg.* 29(3):383-90, 2012.

²⁹ Graham ME, Jawrani, NT, Chikka A. Extra-Osseous TaloTarsal Stabilization using HyProCure® in Adults: A 5-Year Retrospective Follow-Up. *J Foot Ankle Surg.* 51(1): 23-29, 2012.

³⁰ Graham ME, Jawrani NT, Chikka A, Rogers RJ. Surgical Treatment of Hyperpronation Using an Extra-Osseous TaloTarsal Stabilization Device: Radiographic Outcomes in Adult Patients. *J Foot Ankle Surg.* 51 (5): 548-55, 2012.

³¹ Graham ME, Jawrani, NT. Extra-Osseous Stabilization Devices: A New Classification System. *J Foot Ankle Surg.* 51(5):613-9, 2012.

³² Graham ME. Talotarsal Joint Displacement—Diagnosis and Stabilization Options. *Foot and Ankle Quarterly*, Volume 23, Issue 4, Pages 165-179, winter 2012.

³³ Hazany S, Ly N, Hazany D, Bader S, Ostuka N. Outcomes of subtalar arthroereisis for the planovalgus foot. 21(3):147-50, 2012.

³⁴ Martinelli N, Marinozzi A, Schulze M, Denaro V, Evers J, Bianchi A, Rosenbaum D. Effects of subtalar arthroereisis on the tibiotalar contact characteristics in a cadaver flatfoot model. *J Biomech.* 45(9):1745-8, 2012.

³⁵ Corpus M, Shoffer D, Labovitz J, Hodor L, Yu K. Fracture of the talus as a complication of subtalar arthroereisis. *J Foot Ankle Surg.* 51(1):91-4, 2012.

³⁶ Van Ooij B, Vos CJ, Saouti R. Arthroereisis of the subtalar joint: an uncommon complication and literature review. *J Foot Ankle Surg.* 51(1):114-7, 2012.

³⁷ Brancheau SP, Walker KM, Northcutt DR. An analysis of outcomes after use of the Maxwell-Brancheau Arthroereisis Implant. *J Foot Ankle Surg.* 51(1):3-8, 2012.

³⁸ Metcalfe SA, Bowling FL, Reeves ND. Subtalar joint arthroereisis in the management of pediatric flexible flatfoot: a critical review of the literature. *Foot Ankle Int.* 32(12):1127-39, 2011.

³⁹ Yu T, Yang Y, Yu G. Application progress of subtalar arthroereisis for correction of pediatric flatfoot in children. *Zhonggou Xiu Fu Chong Jian Wai Ke Za Zhi.* 25(2):1513-6, 2011.

⁴⁰ Graham ME, Jawrani NT, Goel VK. Evaluating plantar fascia strain in hyperpronating cadaveric feet following an extra-osseous talotarsal stabilization procedure. *J Foot Ankle Surg.* 50(6):682-6, 2011.

⁴¹ Graham ME, Jawrani NT, Chikka A. Radiographic Evaluation of Navicular Position in the Sagittal Plane—Correction Following an Extra-Osseous TaloTarsal Stabilization Procedure. *J Foot Ankle Surg.* 50(5):551-7, 2011.

⁴² Graham ME, Jawrani, NT, Goel VK. Effect of Extra-Osseous TaloTarsal Stabilization on Posterior Tibial Tendon Strain in Hyperpronating Feet. *J Foot Ankle Surg.* 50(6): 676-81, 2011.

⁴³ Graham ME, Jawrani NT, Goel VK. Effect of extra-osseous talotarsal stabilization on posterior tibial nerve strain in hyperpronating feet: a cadaveric evaluation. *J Foot Ankle Surg.* 50(6):672-5, 2011.

⁴⁴ Graham ME, Jawrani, NT, Goel VK. The Effect of HyProCure® on Tarsal Tunnel Compartment Pressures in Hyperpronating Feet. *J Foot Ankle Surg.* 50(1):44-9, 2011.

⁴⁵ Graham ME, Jawrani, NT, Goel VK. Evaluating Plantar Fascia Strain in Hyperpronating Cadaveric Feet Following an Extra-Osseous TaloTarsal Stabilization Procedure. *J Foot Ankle Surg.* 50(6): 682-86, 2011.

⁴⁶ Highlander P, Sung W, Weil L Jr. Subtalar Arthroereisis. *Clin Podiatr Med Surg.* 28(4):745-54, 2011.

⁴⁷ Grant WP, Garcia-Lavin S, Sabo R. Beaming the columns for

Charcot diabetic foot reconstruction: a retrospective analysis. *J Foot Ankle Surg.* 50(2):182-9, 2011.

⁴⁸ Cook EA, Cook JJ, Basile P. Identifying risk factors in subtalar arthroereisis explantation: a propensity-matched analysis. *J Foot Ankle Surg.* 50(4):395-401, 2011.

⁴⁹ Fernandez de Retana P, Alvarez F, Viladot R. Subtalar arthroereisis in pediatric flatfoot reconstruction. *Foot Anke Clin.* 15(2):323-35, 2010.

⁵⁰ Scharer BM, Black BE, Sockrider N. Treatment of painful pediatric flatfoot with Maxwell-Brancheau subtalar arthroereisis implant a retrospective radiographic review. *Foot Ankle Spec.* 3(2):67-72, 2010.

⁵¹ Koning PM, Heesterbeek PJ, de Visser E. Subtalar arthroereisis for pediatric flexible pes planovalgus: fifteen years experience with the cone-shaped implant. *J Am Podiatr Med Assoc.* 99(5):447-53, 2009.

⁵² Molayem I, Persiani P, Marcovici LL, Rosi S, Calistri A, Villani C. Complications following correction of the planovalgus foot in cerebral palsy by arthroereisis. *Acta Orthop Belg.* 75(3):374-9, 2009.

⁵³ Adelman VR, Szczepanski JA, Adelman RP. Radiographic evaluation of endoscopic gastrocnemius recession, subtalar joint arthroereisis, and flexor tendon transfer for surgical correction of stage II posterior tibial tendon dysfunction: a pilot study. *J Foot Ankle Surg.* 47(5):400-8, 2008.

⁵⁴ Cicchinelli LD, Pascual Huerta J, Garcia Carmona FJ, Fernandez Morato D. Analysis of gastrocnemius recession and medial column procedures as adjuncts in arthroereisis for the correction of

Continued on page 120

pediatric pes planovalgus: a radiographic retrospective study. *J Foot Ankle Surg.* 47(5):385-91, 2008.

⁵⁵ Scialpi L, Mori C, Mori F, Sperti M, Solarino G. Arthroereisis with Giannini's endo-orthotic implant and Pisani's talocalcaneal arthroereisis. A comparison of surgical methods. *Chir Organi Mov.* 92(1):61-5, 2008.

⁵⁶ Chang TJ, Lee J. Subtalar joint arthroereisis in adult-acquired flatfoot and posterior tibial tendon dysfunction. *Clin Podiatr Med Surg.* 24(4):687-97, 2007.

⁵⁷ Jacobs AM. Soft tissue procedures for the stabilization of medial arch pathology in the management of flexible flatfoot deformity. *Clin Podiatr Med Surg.* 24(4):657-65, 2007.

⁵⁸ Lui TH. Endoscopic assisted posterior tendon reconstruction for stage 2 posterior tibial tendon insufficiency. *Knee Surg Sports Traumatol Arthrosc.* 15(10):1228-34, 2007.

⁵⁹ Schon LC. Subtalar arthroereisis: a new exploration of an old concept. *Foot Ankle Clin.* 12(2):329-39, 2007.

⁶⁰ Saxena A, Nguyen A. Preliminary radiographic findings and sizing implications on patients undergoing bioabsorbable subtalar arthroereisis. *J Foot Ankle Surg.* 46(3):175-80, 2007.

⁶¹ Soomekh DJ, Baravaraian B. Pediatric and adult flatfoot reconstruction: subtalar arthroereisis versus realignment osteotomy surgical options. *Clin Podiatr Med Surg.* 23(4):695-708, 2006.

⁶² Needleman RL. A surgical approach for flexible flatfeet in adults including a subtalar arthroereisis with the MBA sinus tarsi implant. *Foot Ankle Int.* 27(1):9-18, 2006.

⁶³ Vora AM, tie TR, Parks BG, Schon LC. Correction of moderate

and severe acquired flexible flatfoot with medializing calcaneal osteotomy and flexor digitorum longus transfer. *J Bone Joint Surg AM.* 88(8):1726-34, 2006.

⁶⁴ Needleman RL. Current topic review: subtalar arthroereisis for the correction of flexible flatfoot. *Foot Ankle Int.* 26(4):336-46, 2005.

⁶⁵ Gutierrez PR, Lara MH. Giannini prosthesis for flatfoot. *Foot Ankle Int.* 26(11):918-26, 2005.

⁶⁶ Nelson SC, haycock DM, Little ER. Flexible flatfoot treatment with arthroereisis: radiographic improvement and child health survey analysis. *J Foot Ankle Surg.* 43(3):144-55, 2004.

⁶⁷ Arngio GA, Reinert KL, Salathe EP. A biomechanical model of the effect of subtalar arthroereisis on the adult flexible flat foot. *Clin Biomech (Bristol, Avon).* 19(8):847-52, 2004.

⁶⁸ Viladot R, Pons M, Alaverz F, Omana J. Subtalar arthroereisis for posterior tibial tendon dysfunction: a preliminary report. *Foot Ankle Int.* 24(8):600-6, 2003.

⁶⁹ Gianini S, Ceccarelli F, Vannini F, Baldi E. Operative treatment of flatfoot with talocalcaneal coalition. *Clin Orthop Relat Res.* 411:178-87, 2003.

⁷⁰ Zaret DJ, Myerson MS. Arthroereisis of the subtalar joint. *Foot Ankle Clin.* 8(3):605-17, 2003.

⁷¹ Husain ZS, Fallat LM. Biomechanical analysis of Maxwell-Brancheau arthroereisis implants. *J Foot Ankle Surg.* 41(6):352-8, 2002.

⁷² Maxwell JR, Carro A, Sun C. Use of the Maxwell-Brancheau arthroereisis implant for the correction of posterior tibial tendon dysfunction. *Clin Podiatr Med Surg.* 16(3):479-89, 1999.

⁷³ Rohm J, Zwicky L, Horn Lang T, Salentiny Y, Hintermann B, Knupp M. Mid- to long-term outcome of 96 corrective hindfoot fusions in 84 patients with rigid flatfoot deformity. *Bone Joint J.* 97-B(5):668-74, 2015.

⁷⁴ Yang C, Xu X, Zhu Y, Liu J, Wei B. A Long-term study on the effect of subtalar arthrodesis on the ankle and hindfoot joints. *J Am Podiatr Med Assoc.* 106(1):47-53, 2016.

⁷⁵ Zanolli DH, Nunley JA 2nd, Easley ME. Subtalar fusion Rate in patients with previous ipsilateral ankle arthrodesis. *Foot Ankle Int.* 36(9):1025-8, 2015.

⁷⁶ Corpus M, Shoffer D, Labovitz J, Hodor L, Yu K. Fracture of the talus as a complication of subtalar arthroereisis. *J Foot Ankle Surg.* 51(1):91-4, 2012.

⁷⁷ Van Ooij B, Vos CJ, Saouti R. Arthroereisis of the subtalar joint: an uncommon complication and literature review. *J Foot Ankle Surg.* 51(1):114-7, 2012.

⁷⁸ Lui TH. Spontaneous subtalar fusion: an irreversible complication of subtalar arthroereisis. *J Foot Ankle Surg.* 53(5):652-6, 2014.

⁷⁹ Kumar V, Clough TM. Talar neck fracture—a rare but important complication following subtalar arthroereisis. *Foot (Edinb).* 24(4):169-71, 2014.

⁸⁰ Smith G, Pell JP. Parachute use to prevent death and major trauma related to gravitational challenge: systematic review of randomized controlled trials. *BMJ.* 327:1459-61, 2003.



Dr. Graham is a board certified podiatric foot & ankle surgeon and the inventor of the HyProCure sinus tarsi stent. He founded GraMedica, an orthopedic medical device company in 2003 and received FDA clearance of HyProCure in 2004. He also founded the Graham International Implant Institute, a research and educational company to promote the advancement of the foot and ankle knowledge base. Dr. Graham has authored more than a dozen peer-re-

viewed scientific manuscripts and he lectures extensively all over the world on foot & ankle-related topics.